



**PATIENT PRESENTING CLINICAL SIGNS**

Jacob Lane History: Long-term well controlled diabetic. Acute onset vomiting and anorexia. Treated symptomatically.

**SPECIES** Physical Examination: N/A

Feline Urinalysis: SG 1.049, cocci bacteruria, rest normal.

**BREED** CBC: Lymphopenia.

DSH Serum Biochemistry: Elevated ALT activity, urea, glucose, and bilirubin. Low-normal sodium. Positive fPL.

**SEX** Radiographic Findings: N/A.

MN

**Age ULTRASONOGRAPHIC EXAMINATION OF THE ABDOMEN**

14 years **Urinary System**

**WEIGHT** Full urinary bladder with a normal thickness and appearance of the wall. Normal anechoic urine with no sediment or uroliths evident.

16.7 # Normal trigone area, proximal urethra, and iliac blood vessels.

**INTERPRETED BY** Normal iliac lymph nodes. Ureters not visualized.

Remo Lobetti, BVSc, MMedVet (Med), PhD, Dipl. ECVIM Normal renal size, echogenic appearance, cortico-medullary differentiation, pelvis, and capsule.

**Reproductive System**

N/A.

**IMAGING PERFORMED BY** **Adrenal Glands**

Dr Jackson Poorly visualized.

**HOSPITAL NAME** **Spleen**

Ark Animal Hospital Normal size and echogenic appearance. Smooth homogenous parenchyma, regular curvilinear capsule, and normal vasculature. No inflammatory, neoplastic, infarction, or infiltrative changes evident. Incidental myelolipomas.

**REFERRING VET**

Dr Jackson **Liver**

**INVOICE** Enlarged with rounded edges, hyperechogenic appearance, prominent portal markings, and regular curvilinear capsule. No nodules or masses evident.

304189 **Gall bladder**

**DATE** Small containing normal anechoic bile. Normal thickness and echogenic appearance of the wall. Normal bile duct.

5/3/23



**PATIENT**

***Gastrointestinal***

Jacob Lane

Normal appearance of the stomach, duodenum, small intestine, ileo-cecal junction, and colon with no loss of layering, normal wall thickness and peristalsis, and no distension of the lumen.

**SPECIES**

***Pancreas***

Feline

Enlarged with a hypoechogenic appearance and irregular capsule. Hyperechogenic appearance of the mesentery and fat surrounding the pancreas.

**BREED**

***Free Abdomen***

DSH

No mesenteric lymph lymphadenomegaly.  
No ascites evident.

**SEX**

MN

**Age**

14 years

Primary Findings:

- Pancreatitis.
- Hepatopathy.

**WEIGHT**

16.7 #

Secondary Findings:

- None.

**INTERPRETED BY**

Remo Lobetti, BVSc,  
MMedVet (Med), PhD,  
Dipl. ECVIM

**INTERPRETATION OF THE FINDINGS & FURTHER RECOMMENDATIONS**

Etiologies for the hepatopathy would be reactive secondary to the diabetes and/or pancreatitis, cholangio-hepatitis complex, lipidosis, and infiltrative neoplasia.

**IMAGING PERFORMED BY**

Dr Jackson

Further assessment that could be considered would be urine culture, fPL/PSL assay, and FNA cytology of the liver

**HOSPITAL NAME**

Ark Animal Hospital

Management would be fluid therapy, anti-emetics, opioid analgesics, low-fat intestinal diet, insulin, and ursodiol.

**REFERRING VET**

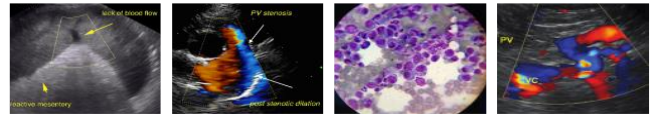
Dr Jackson

**INVOICE**

304189

**DATE**

5/3/23



**PATIENT**

Jacob Lane

**SPECIES**

Feline

**BREED**

DSH

**SEX**

MN

**Age**

14 years

**WEIGHT**

16.7 #

**INTERPRETED BY**

Remo Lobetti, BVSc,  
MMedVet (Med), PhD,  
Dipl. ECVIM

**IMAGING PERFORMED BY**

Dr Jackson

**HOSPITAL NAME**

Ark Animal Hospital

**REFERRING VET**

Dr Jackson

**INVOICE**

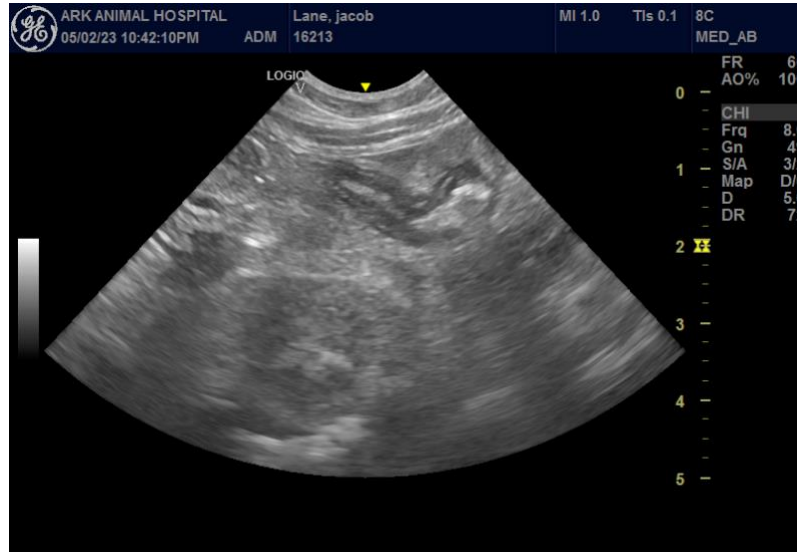
304189

**DATE**

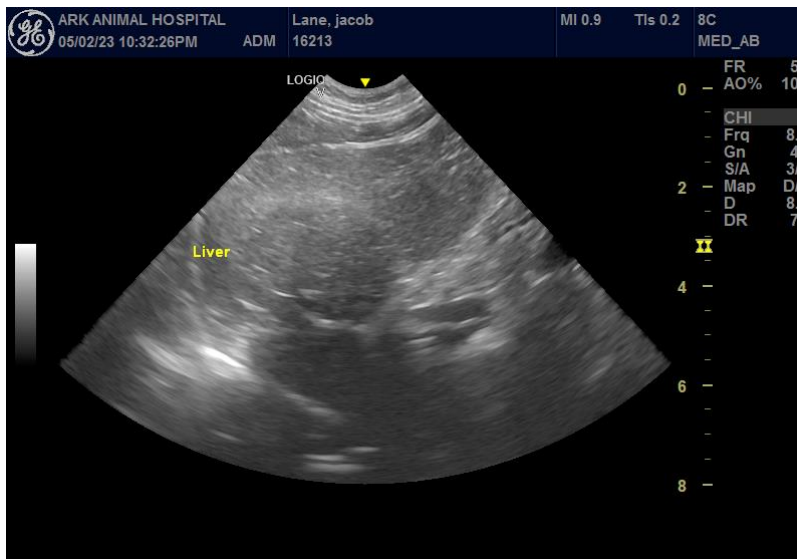
5/3/23

**IMAGES**

**Pancreas**



**Liver**



The information and recommendations provided are based on the images presented by the referring veterinarian. No evaluation can be communicated regarding pathology that was not visible in the image/video clips provided.

Thank you for this referral. If the clinical or image interpretation does not parallel your findings or if I can be of any further assistance, please contact me.

**Remo Lobetti, BVSc, MMedVet (Med), PhD, Dipl. ECVIM (Internal Medicine)**  
[remo.lobetti@sonopath.com](mailto:remo.lobetti@sonopath.com)